

Excerpt from JBJS Style Guide

Figures (last updated 4/1/16)

Place the legends for all figures on a separate page at the end of the manuscript. Identify figures by Arabic numerals, with a capital letter (A, B, C, etc.) separated by a hyphen if the author has distinguished the figures in that way. Use a label for each figure and begin the legend underneath. Note the use of boldface in the examples below.

EXAMPLES:

When images are different panels of one figure (with A, B, C, D on the images themselves) and more than one panel can be described in one sentence:

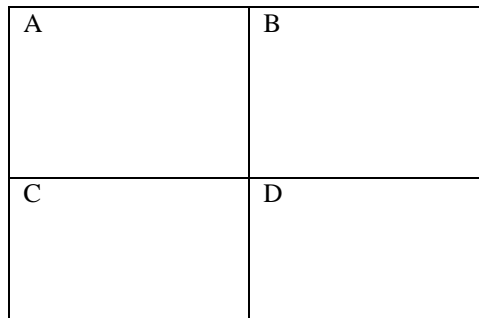


Fig. 1

Photomicrographs showing the cyst (**Fig. 1-A**) and tumor (**Fig. 1-B**) and radiographs showing the left (**Fig. 1-C**) and right (**Fig. 1-D**) fractures.

When images are different panels of one figure (with A, B, C, D on the images themselves), and each panel must be described in a separate sentence.

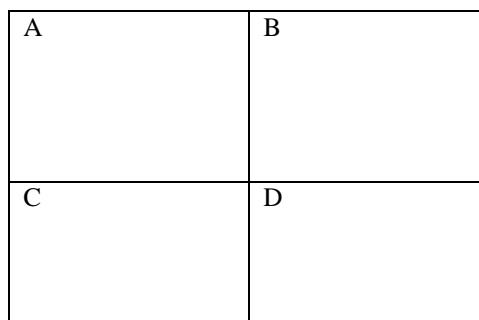


Fig. 1

Figs. 1-A through 1-D. Radiographs of Case 2. **Fig. 1-A** Radiograph made three months preoperatively showing the fracture. **Fig. 1-B** Micrograph showing the tumor. Note the fibrous tissue. **Fig. 1-C** Intraoperative photograph showing the fracture (arrow). **Fig. 1-D** At the time of follow-up, the patient has excellent function.

When images are different figures (with NO letters on the images themselves but Fig. 1-A, Fig. 1-B, Fig. 1-C, or 1-D labeling each figure) and more than one image can be described in one sentence.



Fig. 1-A



Fig. 1-B



Fig. 1-C



Fig. 1-D

Photomicrographs showing the cyst (**Fig. 1-A**) and tumor (**Fig. 1-B**) and radiographs showing the left (**Fig. 1-C**) and right (**Fig. 1-D**) fractures.

When images are different figures (with NO letters on the images themselves but Fig. 1-A, Fig. 1-B, Fig. 1-C, or 1-D labeling each figure) and each figure must be described in a separate sentence.




Fig. 1-A



Fig. 1-B



Fig. 1-C



Fig. 1-D

Fig. 1-A

Figs. 1-A through 1-D Radiographs of Case 2. **Fig. 1-A** Radiograph made three months preoperatively showing the fracture.

Fig. 1-B

Micrograph showing the tumor. Note the fibrous tissue.

Fig. 1-C

Intraoperative photograph showing the fracture (arrow).

Fig. 1-D

At the time of follow-up, the patient has excellent function.

Note that if some figures can be described in the same sentence and others need a separate sentence you can put some side by side:




Fig. 1-A

Fig. 1-B



Fig. 1-C



Fig. 1-D

Fig. 1-A Fig. 1-B

Figs. 1-A through 1-D Radiographs of Case 2. **Figs. 1-A and 1-B** Anteroposterior and lateral radiographs made three months preoperatively showing the fracture.

Fig. 1-C

Intraoperative photograph showing the fracture (arrow).

Fig. 1-D

At the time of follow-up, the patient has excellent function.

Figures should be cited in the text as:

(Fig. 1)

(Figs. 1 and 2)

(Figs. 1-A and 1-B)

(Figs. 1-A, 1-B, and 1-C)

(Figs. 1-A through 1-D)